

Case report

Open Access

## Repair of ascending aorta pseudoaneurysm without circulatory arrest in redo patient

Stefano Auriemma\*, Paolo Magagna, Ayman Sallam, Nicola Lamascese and Alessandro Fabbri

Address: Division of Cardiac Surgery San Bortolo Vicenza Hospital, Vicenza, Italy

Email: Stefano Auriemma\* - stefano.auriemma@tin.it; Paolo Magagna - paolo.magagna@libero.it; Ayman Sallam - ayman\_sal@libero.it; Nicola Lamascese - nicola.lamascese@libero.it; Alessandro Fabbri - alessandro@fabbrispace.it

\* Corresponding author

Published: 24 March 2006

Received: 22 January 2006

World Journal of Emergency Surgery 2006, 1:2 doi:10.1186/1749-7922-1-2

Accepted: 24 March 2006

This article is available from: <http://www.wjes.org/content/1/1/2>

© 2006 Auriemma et al; licensee BioMed Central Ltd.

This is an Open Access article distributed under the terms of the Creative Commons Attribution License (<http://creativecommons.org/licenses/by/2.0>), which permits unrestricted use, distribution, and reproduction in any medium, provided the original work is properly cited.

### Abstract

A pseudoaneurysm of the ascending aorta is an unusual and potentially fatal complication after aortic surgical operations. TEE and CT scan are the investigations of choice. Surgical treatment is mandatory. We describe the successful management of a pseudoaneurysm of the ascending aorta, with aorto-sternal-cutaneous fistula requiring right axillary and femoral artery cannulation with Remote Access Perfusion® aortic cannula (Estech®, California, USA). Behaving like this we avoid hypothermic circulatory arrest, provide safe reentry and prevent an impending rupture.

### Background

Mediastinal pseudoaneurysms are rare but life-threatening complications of thoracic aortic operations [1,2]. Predisposing factors are the dissection of the native aorta, infection, connective tissue disorders, preoperative chronic hypertension, aortic calcification and blowout of the aortotomy site [1].

A pseudoaneurysm of the ascending aorta could present itself as a pulsatile mass, angina due to graft compression, chest pain caused by local erosion, dysphagia or stridor [2].

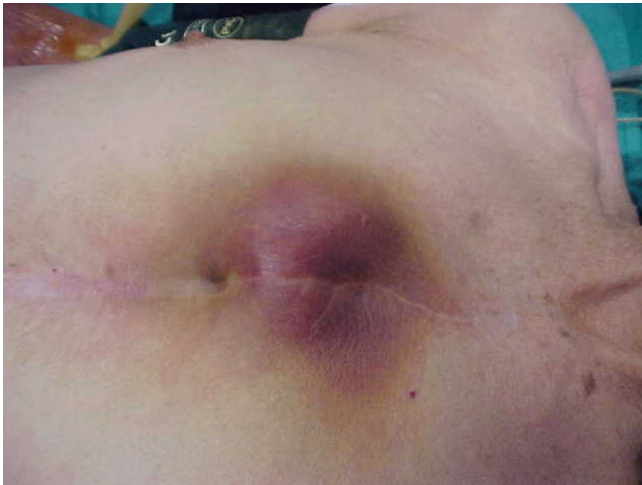Redo operations for large pseudoaneurysm of the ascending aorta are a surgical challenge [3]. Sternal reentry by itself can precipitate fatal haemorrhage or cerebral air embolism.

Our technique points out the use of right axillary artery cannulation and endoclamping perfusing aortic cannula to avoid hypothermic circulatory arrest [5].

This allows us to prevent an impending rupture, to repair the defect and to preserve the brain and the other organs during the procedure.

### Case report

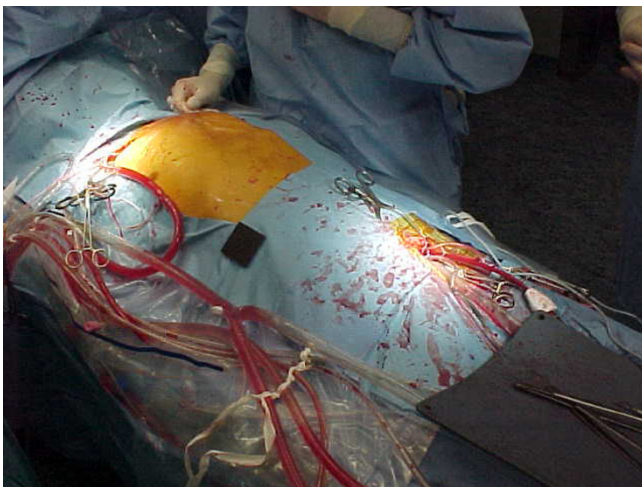
Our case treats of a 79-years-old man who has electively undergone aortic valve and ascending aorta replacement for degenerative aortic disease using a number 25 Edwards Lifesciences porcine stentless bioprosthesis (Edwards, California, USA). He was readmitted 4 months later with fever, intermittently painful and pulsatile swelling over the upper third of the sternum that appeared over a period of 15 days and had gradually increased in size to attain its present size of 6 × 4 cm (Fig. 1).



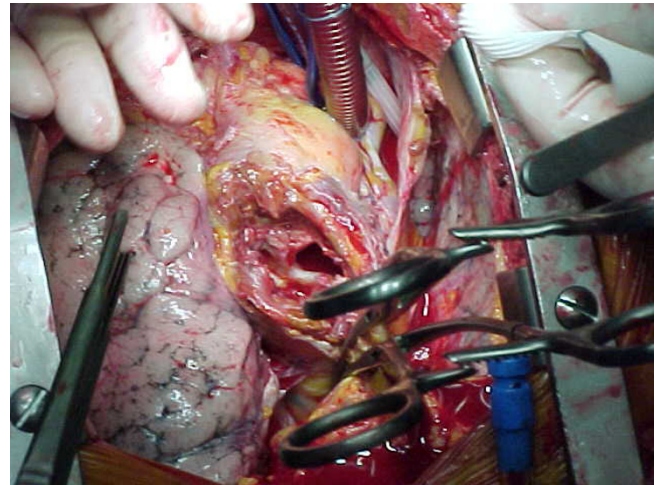
**Figure 1**  
Patient's antero-lateral view showing pulsatile erythematous swelling over the upper third of the sternum.

A preoperative TEE showed a pseudoaneurysm with high flow velocity inside, developed between the prosthesis and the posterior surface of the sternum.

Moderate hypothermic bypass was instituted with cannulation of right axillary artery for antegrade cerebral perfusion and femoral artery with Estech® cannula for aorta endoclamping and perfusion of lower body districts [5] (Fig. 2). The chest was opened through the previous scar reducing the CPB flows and obtaining digital control over the defect on the aorta. Subsequently a vent cannula has been placed in the right superior pulmonary vein to decompress the left side of the heart. The extrathoracic component of the pseudoaneurysm was opened and the



**Figure 2**  
Arterial perfusion sites.



**Figure 3**  
Intra-operative view showing the defect in the ascending aorta.

clots evacuated. Adhesions over the right ventricle were taken down, and both pleura were opened. Clots in front of the aorta were evacuated to reveal one main defect at the previous aortotomy site measuring 2 × 2 cm (Fig. 3). The bioprosthesis was explored through the defect and was found to be normal. The defect was closed using 3 × 3 cm polytetrafluoroethylene patch.

After deairing the patient was rewarmed and the heart picked up after single electric shock in sinus rhythm. The weaning from the bypass was easy.

The patient remained hemodynamically stable on minimal inotropic support and was extubated in second post-operative day without neurologic complications.

The cause of the pseudoaneurysm appeared to be an infection at the previous aortotomy site; the cultures taken from adjacent tissues and intraluminal blood clots were positive for *Staphylococcus aureus*.

### Discussion

Pseudoaneurysm of the ascending aorta after aortic procedure usually occur at anastomotic suture lines or at aortotomy, aortic cannulation or aortic needle puncture sites. Most episodes have infective causes [1]

Contrast CT scanning, RMI and echocardiography are useful in the diagnosis of pseudoaneurysm of the ascending aorta. Surgical repair is mandatory [1,4].

The most important issue is to protect the brain and systemic perfusion before opening the chest, because an inadvertent pseudoaneurysm rupture during a repeat ster-

notomy or mediastinal dissection can lead to a catastrophic intraoperative haemorrhage.

The use of CPB with cannulation of right axillary and femoral arteries and the use of Remote Access Perfusion® aortic cannula have helped us to prevent an impending rupture. This has avoided deep hypothermic circulatory arrest and has allowed us to effect an adequate and safe repair without time limits [5].

## References

1. Sabri MN, Henry D, Wechler AS, Di Sciascio G, Vetrovec GW: **Late complications involving the ascending aorta after cardiac surgery, recognition and management.** *Am Heart J* 1991, **121**:1779-83.
2. Mohammadi S, Bonnet N, Leprince P, Kolsi M, Rama A, Pavie A, Gandjbakhch I: **Reoperation for false aneurysm of the ascending aorta after its prosthetic replacement: surgical strategy.** *Ann Thorac Surg* 2005, **79**(1):147-52. discussion 152
3. Sullivan KL, Steiner RM, Smullens SN, Griska L, Meister SG: **Pseudoaneurysm of the ascending aorta following cardiac surgery.** *Chest* 1988, **93**:38-43.
4. Gaudino M, Alessandrini F, Canosa C, Possati G: **Repair of an ascending aorta pseudoaneurysm by way of superior ministernotomy.** *Ann Thorac Surg* 1999, **67**(6):1798-800.
5. D'Attelis N, Diemont FF, Julia PL, Cardon C, Fabiani JN: **Management of pseudoaneurysm of the ascending aorta performed under circulatory arrest by port access.** *Ann Thorac Surg* 2001, **71**:1010-1.

Publish with **BioMed Central** and every scientist can read your work free of charge

*"BioMed Central will be the most significant development for disseminating the results of biomedical research in our lifetime."*

Sir Paul Nurse, Cancer Research UK

Your research papers will be:

- available free of charge to the entire biomedical community
- peer reviewed and published immediately upon acceptance
- cited in PubMed and archived on PubMed Central
- yours — you keep the copyright

Submit your manuscript here:  
[http://www.biomedcentral.com/info/publishing\\_adv.asp](http://www.biomedcentral.com/info/publishing_adv.asp)

